

577 nm MicroPulse™ Laser Therapy Dramatically Reduces Macular Thickness in a Patient with Recalcitrant Uveitis



Jeevan Mathura, MD, is an assistant professor of ophthalmology at George Washington University in Washington, D.C. He sees patients at GW Medical Faculty Associates.

I first began using MicroPulse Laser Therapy (MPLT) in my practice in Nov. 2011 as a way to treat macular edema involving the fovea with less risk than the traditional thermal laser approach. In addition, I was hoping to reduce the frequency of injection therapy for my patients, many of whom were expressing their displeasure with it. Now, I use MPLT most often to treat diabetic macular edema and central serous chorioretinopathy (CSC). Published studies have shown MPLT to be a safe and effective treatment for these conditions as well as retinal vein occlusion, proliferative diabetic retinopathy and primary open-angle glaucoma.^{1,2}

I've also used MPLT in a small number of cases to treat patients with uveitis and cystoid macular edema following cataract surgery.

MicroPulse technology delivers laser energy in a unique way. A continuous-wave laser beam is chopped into a train of short, repetitive, low energy pulses separated by brief rest periods. The rest periods allow the tissue to cool between pulses, which minimizes or prevents tissue damage, and can produce outcomes equal or superior to conventional thermal laser therapy.³ Because retinal pigment epithelium tissue remains viable, it's able to participate in a therapeutic response, which is believed to include upregulation of anti-angiogenic factors. MPLT can be used safely in combination with other treatment modalities, and it is repeatable if necessary.

PATIENT HISTORY AND PRESENTATION

A 63-year-old male with recalcitrant posterior uveitis had been referred to me about 2 years prior to his MPLT treatment so he could be monitored for ocular effects of diabetes. In addition to diabetes, he also had high blood pressure.

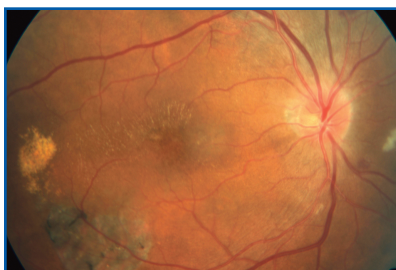


Figure 1. Nov. 2011 right eye | CST 681 μm VA 20/400.

In Nov. 2009, I observed a neuroretinitis-like presentation in the patient's right eye. Similar signs were present in the left eye, but were much less severe. His visual acuity (VA) in the left eye was 20/50 and the macula was flat and dry on time-domain optical coherence tomography (OCT). A workup ruled out an infectious cause. The patient returned in Nov. 2011, at which time he said he had been experiencing flashing lights and floaters for 5 months in his right eye: VA was 20/400 and central subfield thickness (CST) on spectral-domain OCT was 681 μm (Figure 1).

"MPLT was the only attempted treatment that resulted in resolution of the macular edema..."

INITIAL TREATMENT

At the Nov. 2011 visit, the patient was treated with an intravitreal injection of bevacizumab (Avastin, Genentech) in the right eye and referred to our uveitis service for further workup. Lab tests confirmed that the patient had sarcoidosis.

Between Jan. 2012 and Nov. 1, 2012, the patient's right eye was treated with three bevacizumab injections, two periocular steroid injections and an intravitreal steroid injection. At some visits during this period, macular edema decreased, but it continued to recur and become more severe, exceeding 1,000 μm at times. VA never improved to better than 20/150, and at some visits, was counting fingers (Figure 2). Also during this period, macular edema in the patient's left eye became more severe, however he declined immunomodulatory therapy and the dexamethasone (Ozurdex, Allergan) implant as a potential treatment for the left eye.

MICROPULSE LASER THERAPY

On Nov. 29, 2012, 4 weeks after the patient's right eye was treated with an intravitreal steroid injection, large amounts of fluid, hard exudates and a full-appearing optic nerve with blurred margins were noted in that eye: CST was 727 μm and VA was 20/200 (Figure 3). In addition to macular edema, the eye had developed CSC, which was likely related to the ocular steroid treatment, because a pigment epithelium detachment (PED) was now evident. The patient expressed frustration that he had received so much treatment without a

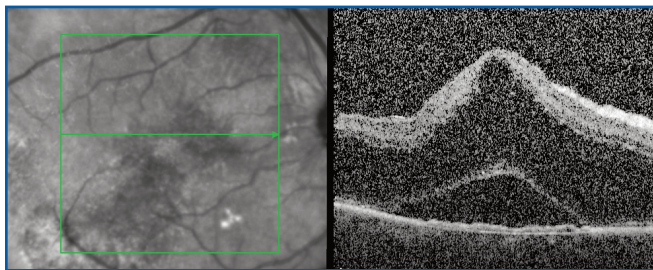


Figure 2. Sept. 2012 | right eye post numerous steroid and intravitreal bevacizumab injections | CST >1,078 μm | VA 20/400.

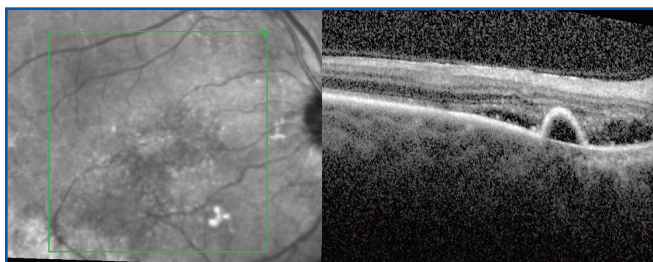


Figure 3. Nov. 2012 | right eye 4 weeks post intravitreal steroid injection | large amounts of fluid, hard exudates, full-appearing optic nerve with blurred margins, CSC and a PED | CST 727 μm | VA 20/200.

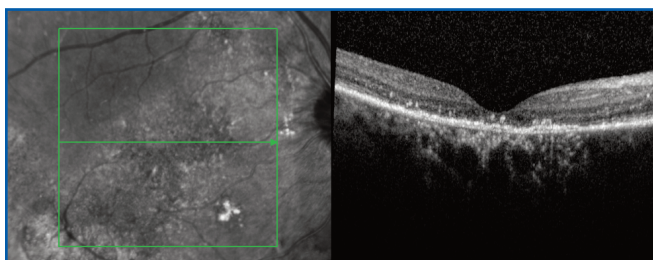


Figure 4. Jan. 2013 | right eye 7 weeks post MPLT | CST 164 μm | VA 20/400.

good outcome and refused further injections in that eye. At this point, he agreed to undergo MPLT.

As I do before each MPLT treatment, I did a test burn outside the vascular arcades on flat retina. With the IRIDEX IQ 577™ laser in continuous-wave mode set to a spot size of 200 μm and an exposure duration of 100 ms, and using a Mainster Focal lens, I titrated the power upward in increments of 10 mW, moving to a new location each time, until I observed a barely visible tissue reaction at 100 mW. For MPLT, I switched the laser to MicroPulse and adjusted the laser power and duty cycle (Table 1).

The patient's first post-MPLT visit was Dec. 13, 2012, at which time CST was much improved at 334 μm . Although his VA was 20/400, he reported being able to see more clearly. The patient returned for follow-up

TABLE 1. TREATMENT PARAMETERS

IRIDEX IQ 577 MPLT for recalcitrant uveitis (tailored to this particular case)

- Wavelength: 577 nm
- Spot size on slit lamp adapter: 200 μm
- Contact lens: Mainster Focal
- Power: 400 mW based on 4x the power determined from a continuous-wave test burn; large amounts of fluid present. (Note that in more typical cases, I've found 3x the test burn power to be very effective.)
- Exposure duration: 100 ms
- Duty cycle: 5%
- MicroPulse delivery: high-density; 1,500 confluent spots over the edematous area based on OCT.

Jan. 17, 2013. His VA remained 20/400, but spectral-domain OCT showed the fluid in the treated eye had resolved. CST was 164 μm . Unfortunately, the IS/OS junction was disrupted due to prolonged edema, which suggests improvement in VA may not be possible (Figure 4).⁴

IMPLICATIONS FOR MY TREATMENT APPROACH

Interestingly, in this case of recalcitrant uveitis, MPLT was the only attempted treatment that resulted in resolution of the macular edema, which was quickly accomplished. The outcome indicated to me that MPLT may be more effective against severe edema than I had previously thought. In the past, I tended to use MPLT predominantly in cases of mild edema that were close to the fovea and in which I preferred not to treat with conventional laser. I am now more likely to consider MPLT in more severe cases and prior to injections, and I look forward to further evaluation of the treatment modality in cases similar to this one. ■

REFERENCES

1. Luttrull JK, Dorin G. Subthreshold diode micropulse laser photocoagulation (SDM) as invisible retinal phototherapy for diabetic macular edema: a review. *Curr Diabetes Rev.* 2012;8(4):274-284.
2. Sivaprasad S, Elagouz M, McHugh D, Shona O, Dorin G. Micropulsed diode laser therapy: evolution and clinical applications. *Surv Ophthalmol.* 2010;55(6):516-530.
3. Vujosevic S, Bottega E, Casciano M, Pilotto E, Convento E, Midena E. Microperimetry and fundus autofluorescence in diabetic macular edema: subthreshold micropulse diode laser versus modified early treatment diabetic retinopathy study laser photocoagulation. *retina* 2010;30(6):908-916.
4. Hayashi H, Yamashiro K, Tsujikawa A, Ota M, Otani A, Yoshimura N. Association between foveal photoreceptor integrity and visual outcome in neovascular age-related macular degeneration. *Am J Ophthalmol.* 2009;148(1):83-89.

Treatment techniques and opinions presented in this case report are those of the author. IRIDEX assumes no responsibility for patient treatment and outcome. IRIDEX, IRIDEX logo are registered trademarks, and MicroPulse is a trademark of IRIDEX Corporation.